

DIGITAL DATA ACQUISITION FOR A CAD/CAM-FABRICATED TITANIUM FRAMEWORK AND ZIRCONIUM OXIDE RESTORATIONS FOR AN IMPLANT-SUPPORTED FIXED COMPLETE DENTAL PROSTHESIS

**Wei-Shao Lin, DDS,^a Michael J. Metz, DMD, MSD, MS, MBA,^b
Adrien Pollini, DDS,^c Athanasios Ntounis, DDS, MS,^d and
Dean Morton, BDS, MS^e**

University of Louisville School of Dentistry, Louisville, KY

This dental technique report describes a digital workflow with digital data acquisition at the implant level, computer-aided design and computer-aided manufacturing fabricated, tissue-colored, anodized titanium framework, individually luted zirconium oxide restorations, and autopolymerizing injection-molded acrylic resin to fabricate an implant-supported, metal-ceramic-resin fixed complete dental prosthesis in an edentulous mandible. The 1-step computer-aided design and computer-aided manufacturing fabrication of titanium framework and zirconium oxide restorations can provide a cost-effective alternative to the conventional metal-resin fixed complete dental prosthesis. (J Prosthet Dent 2014;112:1324-1329)

The implant-supported, screw-retained, metal-resin, fixed complete dental prosthesis that consisted of a metal framework, resin denture teeth, and acrylic resin veneering material has a long history of use in implant prosthodontics.¹⁻³ Although it is a well-documented treatment option with a high survival rate of the prosthesis,⁴ many prosthesis-related complications are known. Results of a meta-analysis⁵ suggested that the most common prosthesis-related complication was acrylic resin veneer fracture (cumulative 15-year complication rates, 66.6%) and denture teeth wear (cumulative 15-year complication rates, 43.5%). Acrylic resin veneer fracture may be attributed to design issues and/or technical errors,⁶ whereas the high frequency of tooth wear has been attributed to the inherent limitations of resin denture teeth.⁵⁻⁷ The use of porcelain denture teeth or altering the resin denture teeth surface with amalgam or gold alloy was proposed to slow the process of wear.⁷

A new design of implant-supported, screw-retained fixed complete dental prosthesis has been described.⁸

The design used individual computer-aided design and computer-aided manufacturing (CAD/CAM) fabricated ceramic restorations (with aluminum oxide or zirconium oxide copings) luted onto a CAD/CAM-fabricated titanium framework with pink acrylic resin or ceramic veneering material to mimic missing soft tissue.⁸ The overall cumulative survival rate for this design was 96% with up to 10 years of observations. The titanium framework was fabricated with a double-scan technique with an acrylic resin pattern template. Additional (second) scanning of the completed titanium framework also was needed to fabricate the copings for individual definitive ceramic restorations. Other clinical reports are available of a similar design concept with various framework and ceramic materials.^{9,10} Although it is more costly to use individually luted ceramic restorations than resin denture teeth,¹⁰ this design provides optimal esthetics and reparability in the event of restoration fractures or wear. If repair is needed, then the restorations can be removed individually without

removing the entire prosthesis; the existing restoration designs are preserved in the CAD/CAM software.^{8,9}

Clinical reports^{11,12} found that scannable impression copings (Scan body; Straumann) and an intraoral digital scanner (Cadent iTero; Cadent Ltd) can be used to acquire digital data at the implant level of patients who are partially or completely edentulous. However, a clinical study¹³ reported that this digital pathway was not accurate enough to fabricate a well-fitting framework with 2 dental implants in the edentulous mandible. A verification device and cast were proposed to be used in conjunction with this digital pathway to ensure the passive fit of the definitive prosthesis.¹²

This article describes a cost-effective workflow with digital data acquisition at the implant level. The proposed technique includes a CAD/CAM-fabricated titanium framework, individually luted zirconium oxide restorations, and autopolymerizing injection-molded acrylic resin. The definitive prosthesis presented here is an implant-supported, metal-


^aAssistant Professor, Department of Oral Health and Rehabilitation.

^bAssistant Professor, Department of General Dentistry and Oral Medicine.

^cScholar, Department of Oral Health and Rehabilitation.

^dAssistant Professor, Department of Oral Health and Rehabilitation.

^eProfessor, Chair and Director, Advanced Education in Prosthodontics, Department of Oral Health and Rehabilitation.



1 Definitive implant-level digital data acquisition.



2 Milled polyurethane definitive cast with removable implant analogs and stone base.

ceramic-resin fixed complete dental prosthesis in an edentulous mandible.

TECHNIQUE

First clinical appointment

1. Evaluate existing implants and complete a definitive implant-level impression with scannable impression copings (Scan body RN; Straumann) and an intraoral digital scanner (iTero; Align Technology Inc) (Fig. 1). Transfer the scanned digital data to a dental laboratory (Roy Dental Laboratory) and the manufacturer (Align Technology Inc) for the fabrication of a milled polyurethane definitive cast.

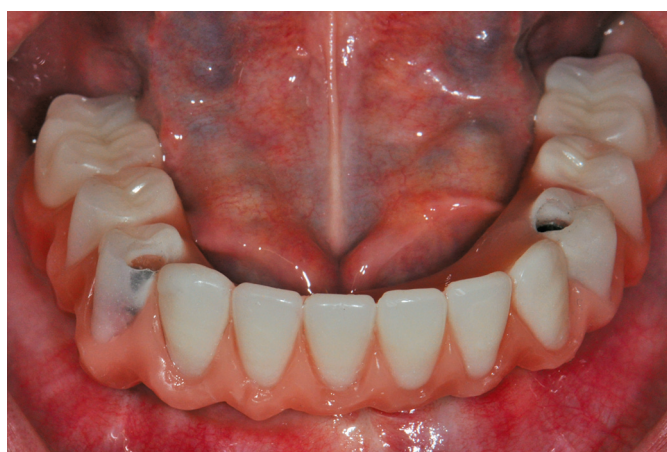First laboratory procedure

1. Insert removable implant analogs (RN Reposition analog; Straumann) into the milled polyurethane definitive cast and fabricate a removable stone base (Fig. 2).¹²

2. Fabricate a segmental verification device and an implant-retained trial base with 2 interim abutments (RN synOcta temporary post, Bridge; Straumann).

Second clinical appointment

1. Evaluate and assemble the segments of the verification device with autopolymerizing acrylic resin (Pattern Resin LS; GC America) and fabricate a verification stone cast.¹²



3 Trial insertion of diagnostic teeth arrangement; molars were then changed to premolar-sized teeth in dental laboratory to minimize length of distal cantilever and to satisfy patient's esthetic demand of smaller teeth.

2. Obtain a facebow transfer and interocclusal record with adjusted implant-retained trial base and registration material (Regisil rigid; Dentsply Prosthetics). Complete the prosthetic tooth selection (BlueLine DCL; Ivoclar Vivadent) and articulation (Hanau Modular Articulator; Whip Mix Corp).

Second laboratory procedure

1. Complete the trial tooth arrangement on the implant-retained trial base.

Third clinical appointment

1. Evaluate the trial tooth arrangement intraorally for esthetics, function, and occlusion (Fig. 3). Adjust the tooth

arrangement to achieve satisfactory clinical outcome as necessary.

Third laboratory procedure

1. Send the trial tooth arrangement, milled polyurethane definitive cast, and verification stone cast to a CAD/CAM facility (Cagenix; Cagenix Inc).

2. Discuss the design of the definitive CAD/CAM fabricated, the tissue-colored anodized titanium framework (AccuFrame IC; Cagenix), and the ceramic restorations (ZenoStar; Wieland Dental Zenotec) with the facility technician. Create a virtual design with a minimum material thickness of 2 mm for the definitive ceramic restorations, a minimum height for the simulated individual abutment structures on the

titanium framework of 4 mm, and a minimum height for all the remaining areas on the titanium framework of 3 to 4 mm (Fig. 4A).

3. Use a continuous inverted T-shape design on the titanium framework (AccuFrame IC) to ensure the strength of the framework if the dimension specification cannot be met because of limited restorative space (Fig. 4B). Splint the definitive ceramic restorations (ZenoStar) at the area with the continuous inverted T-shape design to maximize retention (Fig. 4C). Design the remaining ceramic restorations as single units.

4. Identify the restorations that cover the screw access of the titanium framework (AccuFrame IC) and locate the access openings on the selected restorations without compromising the esthetics (Fig. 4D).

Fourth clinical appointment

1. Verify the fit of the CAD/CAM-fabricated titanium framework (AccuFrame IC) intraorally (Fig. 5A) and with a radiograph. Evaluate the function and esthetics of the ceramic restorations (ZenoStar) (Fig. 5B). Make necessary adjustments with a diamond rotary instrument (Fine Diamonds; Brasseler USA).

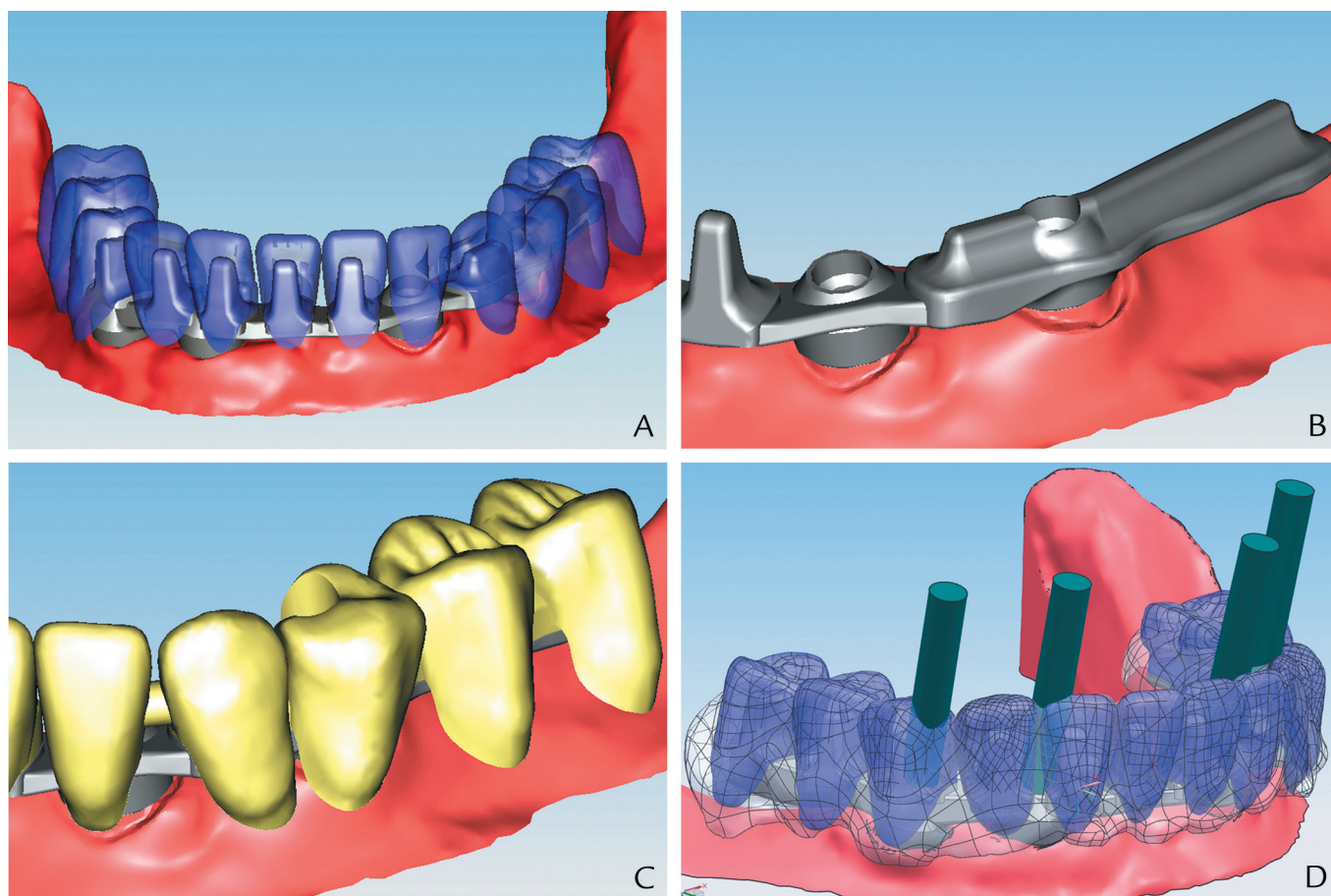
Fourth laboratory procedure

1. Complete the contouring and characterization of the ceramic restorations (ZenoStar) with veneering porcelain (IPS e.max Ceram; Ivoclar Vivadent) and low-fusing nano-fluorapatite glass ceramic (IPS e.max Ceram Shades and Essences; Ivoclar Vivadent).

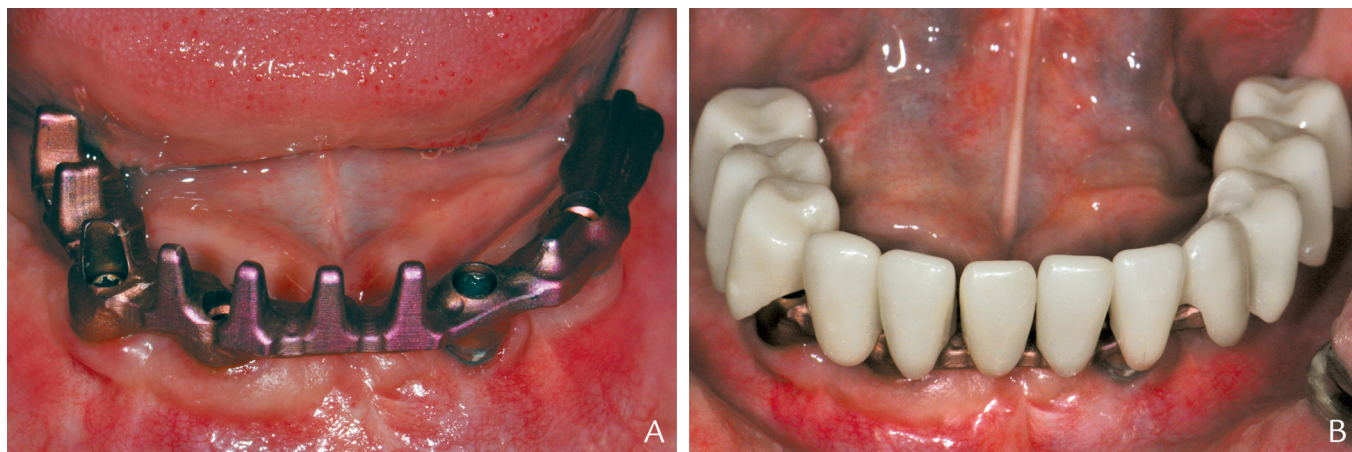
2. Secure the titanium framework (AccuFrame IC) on the milled polyurethane definitive cast and replace the ceramic restorations. Complete the waxing procedure for the definitive prosthesis (Fig. 6A).

3. Secure the implant analogs (RN analog; Straumann) to the titanium framework (AccuFrame IC) and restoration assembly and invest the assembly in the processing flask (Ivobase; Ivoclar Vivadent) with Type III dental stone (Buff Stone; Whip Mix Corp). Place sprue wax (Round Wax Wire Spools, 8 gauge; Kerr Corp) to create the injection channel (Fig. 6B).

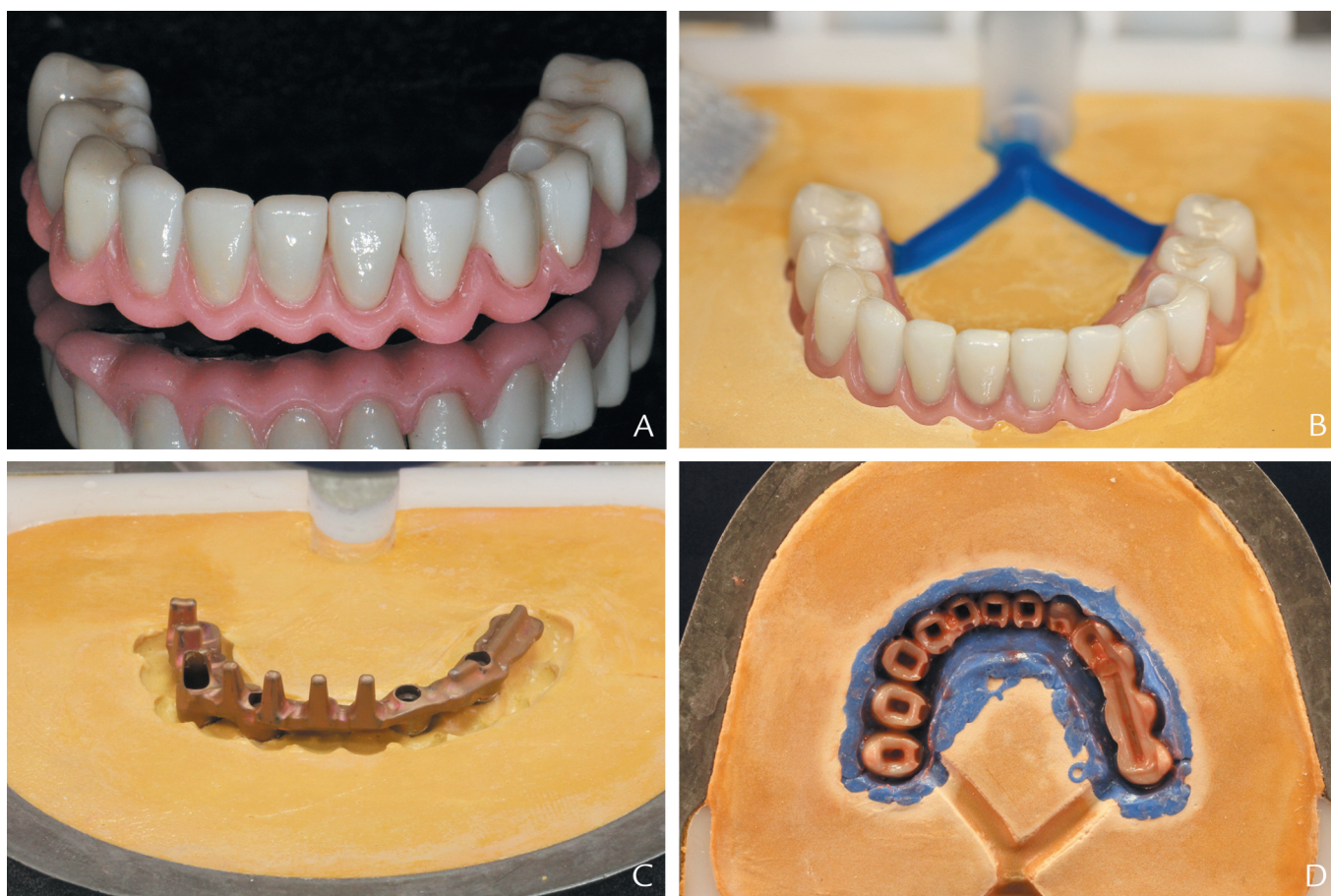
4. Follow the manufacturer's instructions (Ivobase) to complete the flasking procedure with Type III dental stone (Buff Stone) and polyvinyl siloxane material (President Plus Reg



4 A, Design of definitive titanium framework and ceramic restorations. B, Continuous inverted-T-shape design on titanium framework. C, Splinted design of 5-unit definitive ceramic restorations. D, Trajectory of screw access on titanium framework compromised esthetic outcome of mandibular right first premolar, and access opening was not placed on this restoration.



5 A, Trial insertion of tissue-colored anodized titanium framework. B, Trial insertion of definitive titanium framework and ceramic restorations assembly.



6 A, Complete waxing for definitive prosthesis. B, Invested titanium framework and ceramic restorations assembly in processing flask. C, Cleaned titanium framework. D, Separating medium on intaglio surfaces of ceramic restorations and polyvinyl siloxane material.

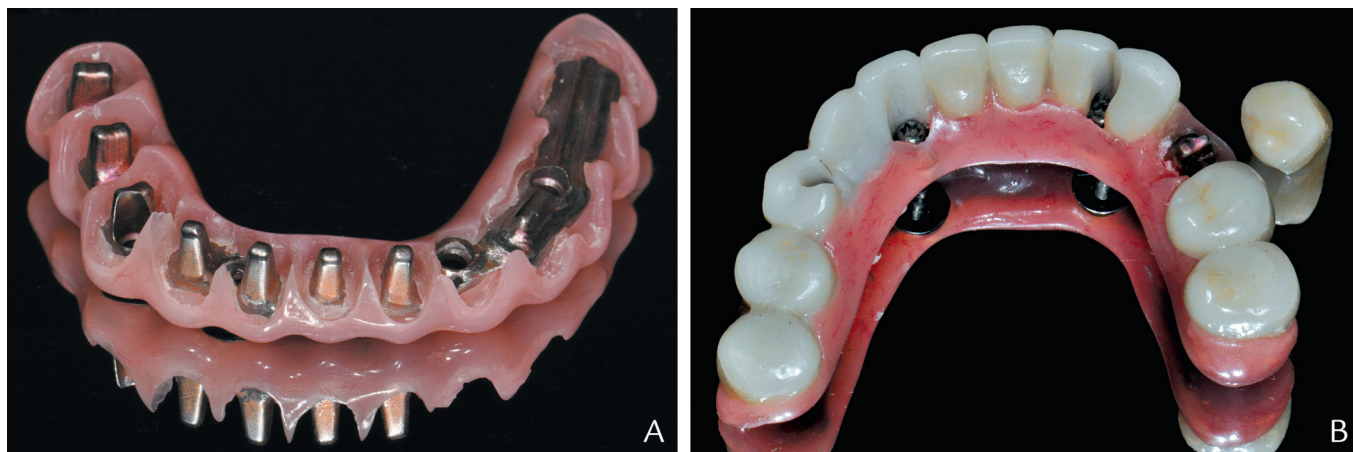
Body; Coltène/Whaledent). Remove all the wax with clean boiling water.

5. Clean and dry the titanium framework (AccuFrame IC) to prevent contamination (Fig. 6C). Apply a separating medium (Rubber Sep; George Taub Products) on the intaglio surfaces of the ceramic

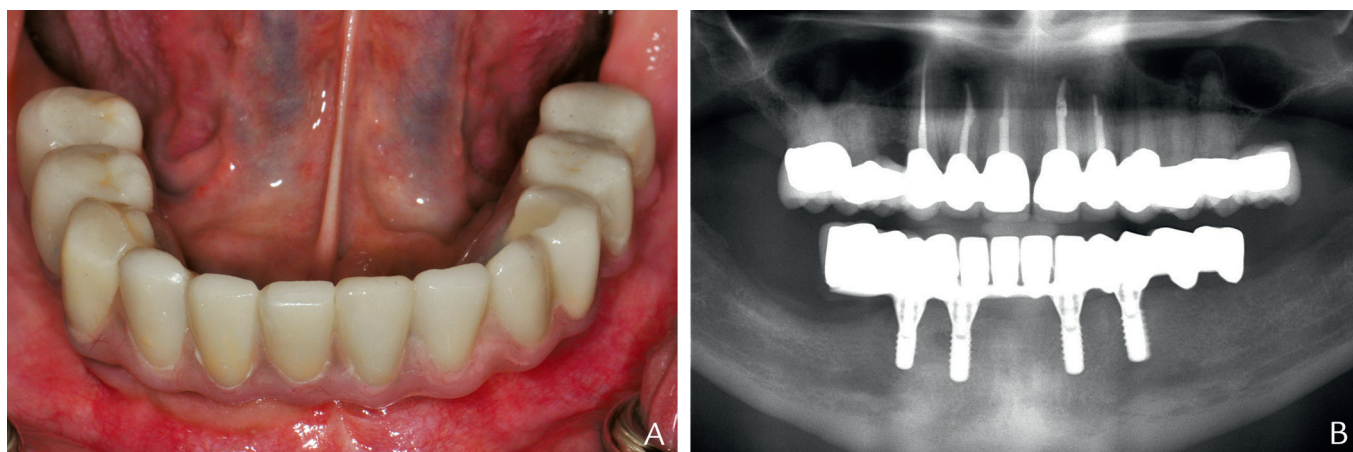
restorations and polyvinyl siloxane material (Fig. 6D). Follow the manufacturer's instructions for mixing the autopolymerizing injection-molded acrylic resin (Ivobase High Impact; Ivoclar Vivadent) and complete the injection and polymerization of the acrylic resin.

6. Adjust the polymerized acrylic resin with a laboratory carbide rotary instrument (Carbide Cutter; Brasseler USA) to ensure the complete seating of the ceramic restorations into the acrylic resin soft tissue moulage (Fig. 7A).

7. Seal the screw access holes of the titanium framework (AccuFrame IC)



7 A, Processed and finished acrylic resin soft tissue mouldage on titanium framework. B, Luted ceramic restorations; mandibular right first premolar without access opening was not luted before insertion appointment.



8 A, Definitive prosthesis. B, Panoramic radiograph of definitive prosthesis.

with cotton pellets. Identify the ceramic restoration that covered the screw access of the titanium framework without an access opening and keep it separate. Lute all remaining restorations to the framework with dual-polymerizing resin cement (Multilink Implant; Ivoclar Vivadent). Remove the excess cement (Fig. 7B).

Fifth clinical appointment

1. Evaluate the fit, function, and esthetics of the metal-ceramic-resin fixed complete dental prosthesis and make necessary adjustments with diamond rotary instruments (Fine Diamonds) on the ceramic restorations and with a laboratory carbide rotary instrument (Carbide Cutter) on the acrylic resin.

2. Secure the prosthesis to the implants with a 35-Ncm preload. Seal all

the screw-access locations in the definitive prosthesis with cotton pellets and single-component resin sealing material (Fermit; Ivoclar Vivadent). Lute the remaining crown with interim cement (TempBond Clear; Kerr Corp) (Fig. 8A, B). Instruct the patient about a home care regimen and schedule periodic maintenance appointments.

DISCUSSION

This article presents a cost-effective workflow for fabricating an implant-supported, metal-ceramic-resin fixed complete dental prosthesis. The capability and flexibility of CAD/CAM software (Cagenix) allow the trial tooth arrangement to be converted to the various titanium framework and ceramic restorations design in a single step. The single-step conversion process decreases the treatment time

and cost when compared with the double-scan technique used in other reports.^{9,10} The software also allowed the access openings to be analyzed and placed on the selected restorations for an implant-supported, screw-retained fixed complete dental prosthesis. If the trajectory of screw access prevents access openings to be placed on the restorations, then they can be luted with interim cement, which enables retrievability. The preserved data from the digital impression and design of the CAD/CAM-fabricated titanium framework and restorations in the CAD/CAM software can be used if repair or refabrication of the definitive cast and/or prosthesis is needed. The possible disadvantages of this proposed workflow are the risk of lost retention between the titanium framework and the ceramic restorations, acrylic resin

veneer fracture, and a higher fabrication cost than the conventional technique with acrylic resin denture teeth. In addition, the monolithic ceramic restorations that directly resulted from the CAD/CAM fabrication process may not achieve the optimal esthetic results. However, the veneering porcelain and low-fusing nanofluorapatite glass ceramic can be used to characterize the ceramic restorations to maximize esthetic outcomes, with additional laboratory cost and time.

SUMMARY

The clinical and laboratory stages for fabricating an implant-supported fixed complete dental prosthesis are presented. The prosthesis consists of the CAD/CAM-fabricated titanium framework, individually luted zirconium oxide restorations, and autopolymerizing injection-molded acrylic resin. Newly developed software allows a more efficient, cost-saving, single-step conversion process for fabricating CAD/CAM-fabricated titanium frameworks and zirconium oxide restorations.

REFERENCES

1. Adell R, Lekholm U, Rockler B, Brånemark P-I. A 15-year study of osseointegrated implants in the treatment of the edentulous jaw. *Int J Oral Surg* 1981;10:387-416.
2. Zarb GA, Schmitt A. The longitudinal clinical effectiveness of osseointegrated dental implants: the Toronto study. Part II: the prosthetic results. *J Prosthet Dent* 1990;64:53-61.
3. Zarb GA, Schmitt A. The longitudinal clinical effectiveness of osseointegrated dental implants: the Toronto study. Part III: problems and complications encountered. *J Prosthet Dent* 1990;64:185-94.
4. Heydecke G, Zwahlen M, Nicol A, Nisand D, Payer M, Renouard F, et al. What is the optimal number of implants for fixed reconstructions: a systematic review. *Clin Oral Implants Res* 2012;23(suppl 6):217-28.
5. Bozini T, Petridis H, Garefis K, Garefis P. A meta-analysis of prosthodontic complication rates of implant-supported fixed dental prostheses in edentulous patients after an observation period of at least 5 years. *Int J Oral Maxillofac Implants* 2011;26:304-18.
6. Papaspyridakos P, Chen CJ, Chuang SK, Weber HP, Gallucci GO. A systematic review of biologic and technical complications with fixed implant rehabilitations for edentulous patients. *Int J Oral Maxillofac Implants* 2012;27:102-10.
7. Purcell BA, McGlumphy EA, Holloway JA, Beck FM. Prosthetic complications in mandibular metal-resin implant-fixed complete dental prostheses: a 5 to 9 year analysis. *Int J Oral Maxillofac Implants* 2008;23:847-57.
8. Maló P, de Araújo Nobre M, Borges J, Almeida R. Retrievable metal ceramic implant-supported fixed prostheses with milled titanium frameworks and all-ceramic crowns: retrospective clinical study with up to 10 years of follow-up. *J Prosthodont* 2012;21:256-64.
9. Maló P, de Sousa ST, De Araújo Nobre M, Moura Guedes C, Almeida R, Roma Torres A, et al. Individual lithium disilicate crowns in a full-arch, implant-supported rehabilitation: a clinical report. *J Prosthodont* 2014;23:495-500.
10. Cho Y, Raigrodski AJ. The rehabilitation of an edentulous mandible with a CAD/CAM zirconia framework and heat-pressed lithium disilicate ceramic crowns: a clinical report. *J Prosthet Dent* 2014;111:443-7.
11. Lin WS, Harris BT, Morton D. The use of a scannable impression coping and digital impression technique to fabricate a customized anatomic abutment and zirconia restoration in the esthetic zone. *J Prosthet Dent* 2013;109:187-91.
12. Lin WS, Harris BT, Zandinejad A, Morton D. Use of digital data acquisition and CAD/CAM technology for the fabrication of a fixed complete dental prosthesis on dental implants. *J Prosthet Dent* 2014;111:1-5.
13. Andriessen FS, Rijkens DR, van der Meer WJ, Wismeijer DW. Applicability and accuracy of an intraoral scanner for scanning multiple implants in edentulous mandibles: a pilot study. *J Prosthet Dent* 2014;111:186-94.

Corresponding author:

Dr Wei-Shao Lin
Department of Oral Health and Rehabilitation, Rm 310
School of Dentistry
University of Louisville
501 South Preston Street
Louisville, KY 40292
E-mail: WeiShao.Lin@Louisville.edu

Acknowledgments

The authors thank Roy Dental Laboratory, New Albany, IN, and Cagenix, Memphis, TN for their assistance in this study.

Copyright © 2014 by the Editorial Council for
The Journal of Prosthetic Dentistry.